

Update of Atherectomy Device and Technique for Severely Calcified Lesions



David Geffen
School of Medicine



Michael S. Lee, MD, FACC, FSCAI
Associate Professor
Interventional Cardiology

80 year-old diabetic with ACS

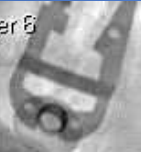Filter: Filter 6

Filter: Filter 6

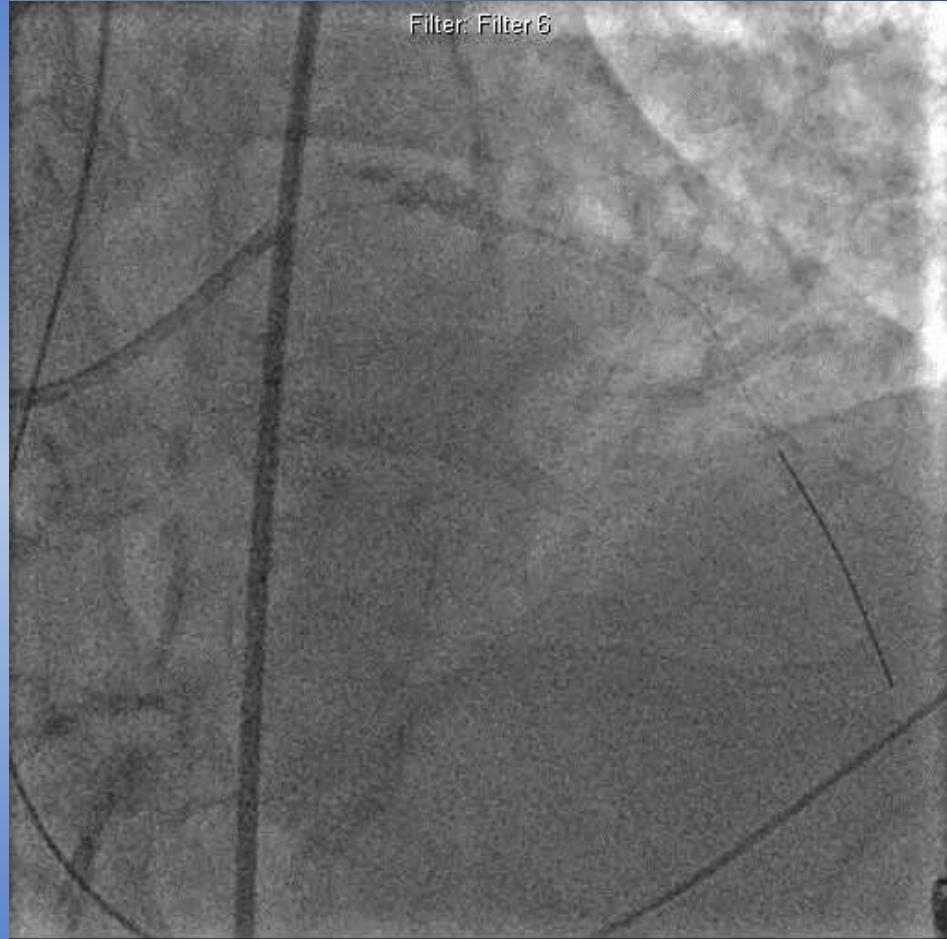Severely calcified proximal LAD



Filter: Filter 6



Filter: Filter 6

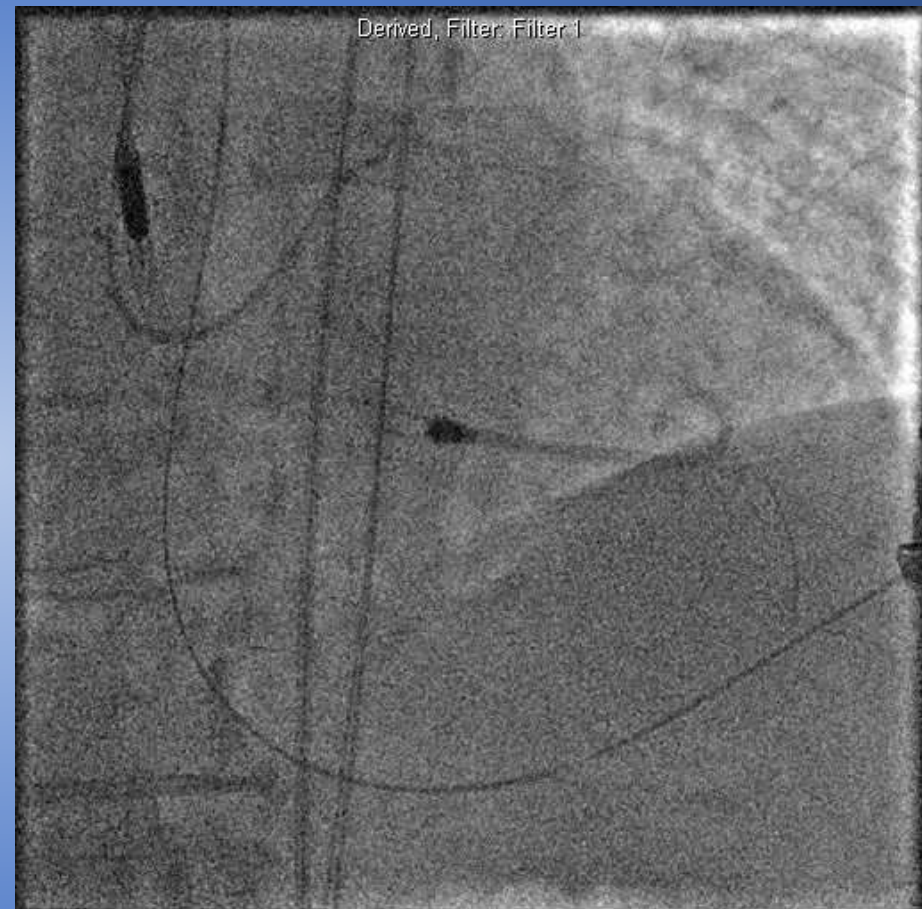
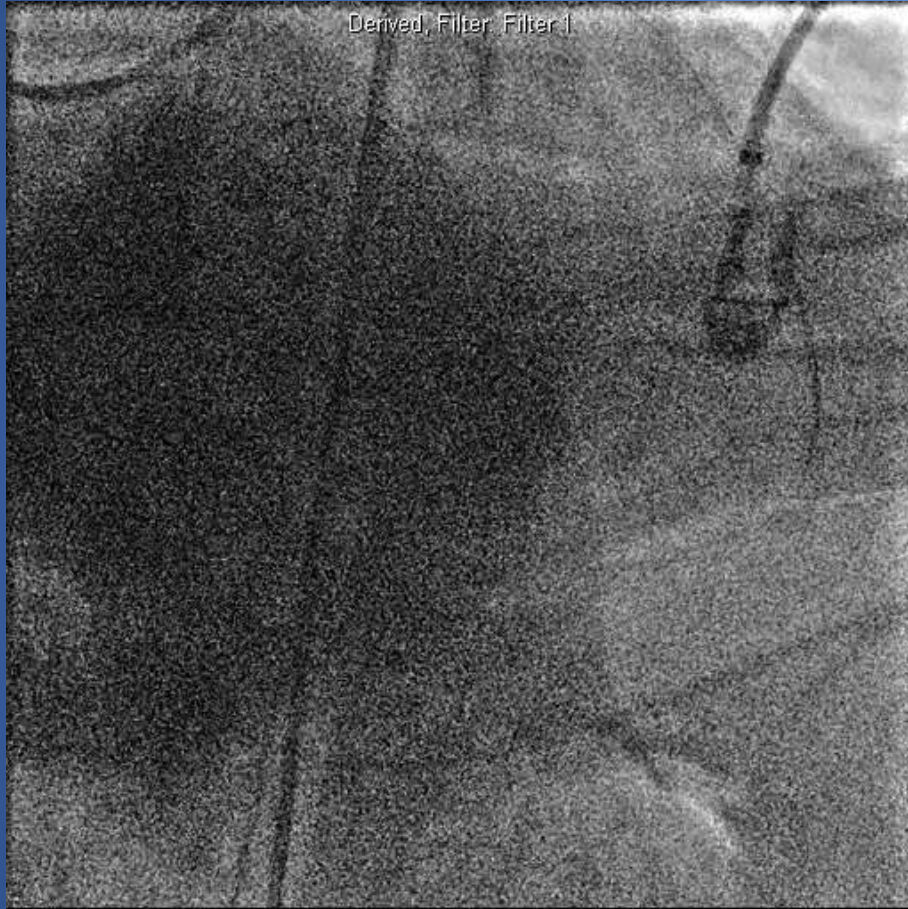


- Multiple, prolonged, high-pressure inflations
- Unable to fully dilate balloon

- Slow flow
- Ischemia
- Contrast staining c/w dissection

- **Cardiac arrest**
- **CPR**

- **Impella insertion**
- **Rotational atherectomy**



- **Intubated, multiple vasopressors**
- **Hemo-metabolic shock, septic shock, multi-organ failure**
- **Died**

Coronary Artery Calcium *a 40-year old problem*

The New England Journal of Medicine

©Copyright, 1979, by the Massachusetts Medical Society

Volume 301

JULY 12, 1979

Number 2

NONOPERATIVE DILATATION OF CORONARY-ARTERY STENOSIS

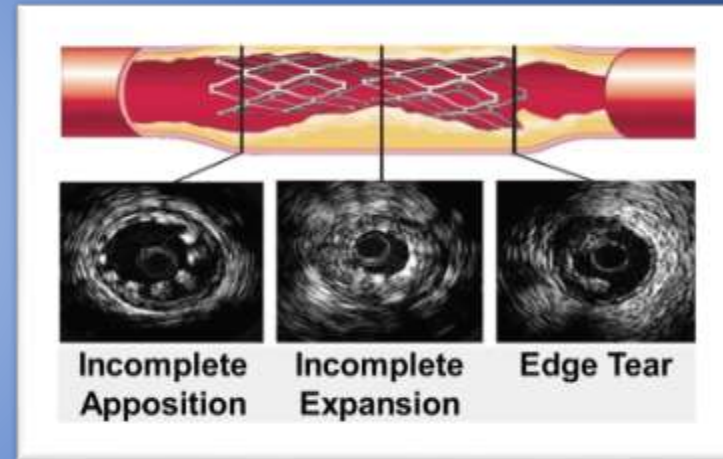
Percutaneous Transluminal Coronary Angioplasty

ANDREAS R. GRÜNTZIG, M.D., ÅKE SENNING, M.D., AND WALTER E. SIEGENTHALER, M.D.

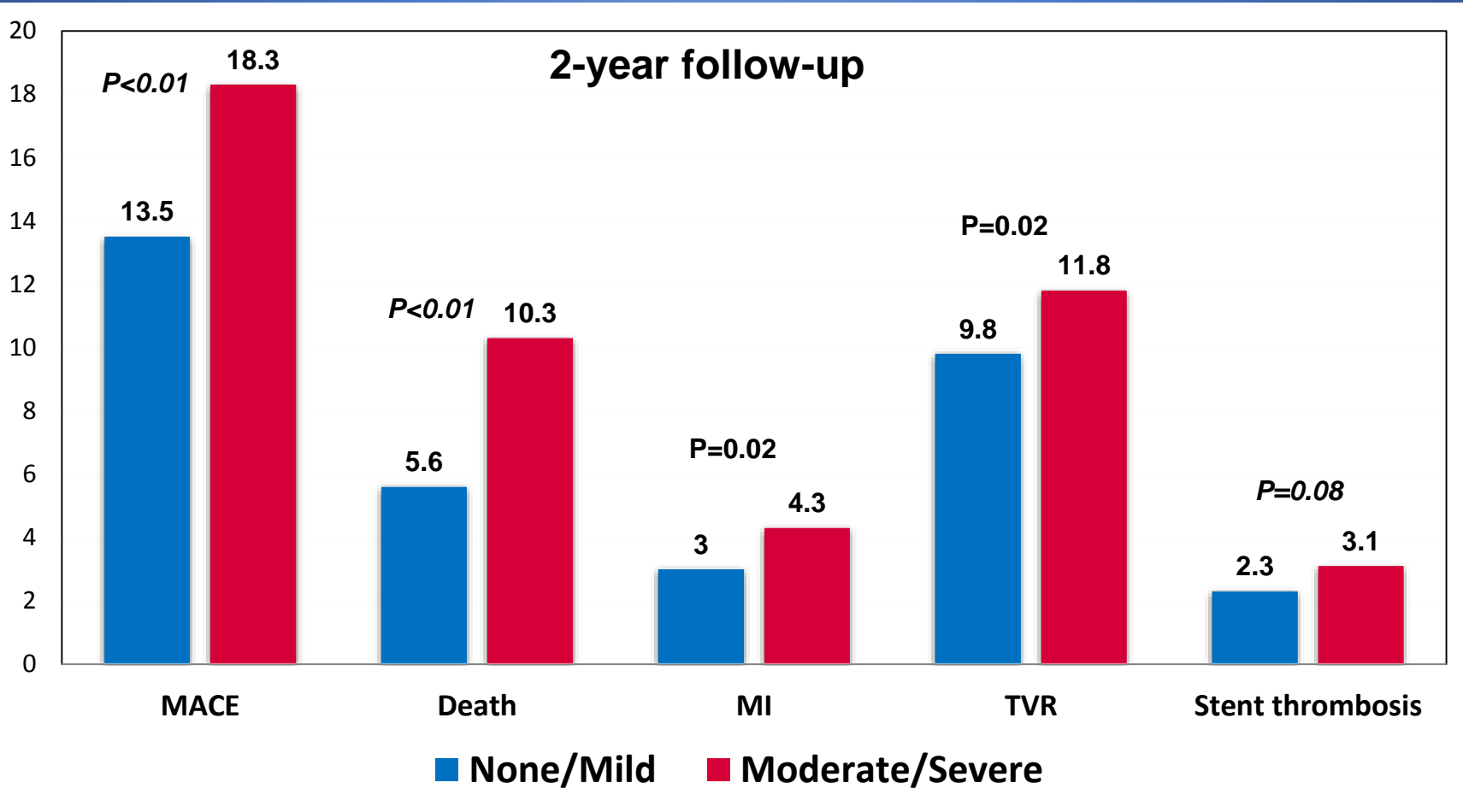
'At present, the [balloon-dilatation] technique is limited by anatomic factors, such as ... calcified stenoses.'¹

Challenges with Calcified Lesions

- **Difficult to treat**
 - Difficult to dilate
 - Prone to dissection during angioplasty
 - Difficulty delivering stent
 - Prevent adequate stent expansion
- **Poor clinical outcomes, including higher MACE**
 - Most trials excluded calcified lesions



Impact of Coronary Artery Calcification in PCI with PES *ARRIVE I and II Registries*



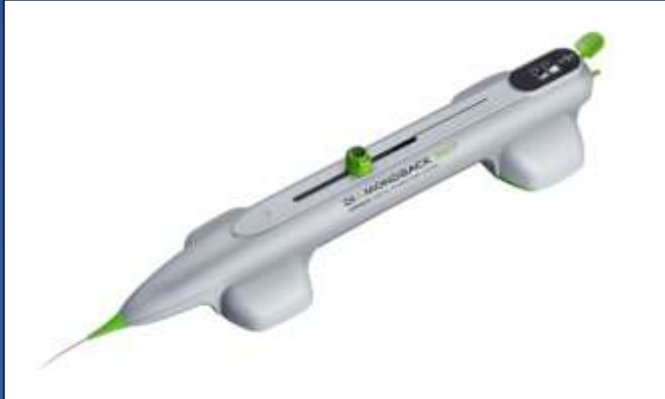
Rationale for Plaque Preparation with Coronary Atherectomy

- Improve procedural success
- Change morphology of lesion
- Facilitates optimal stent expansion
- Reduce complications



Orbital Atherectomy

Mechanism of Action



Differential Sanding:

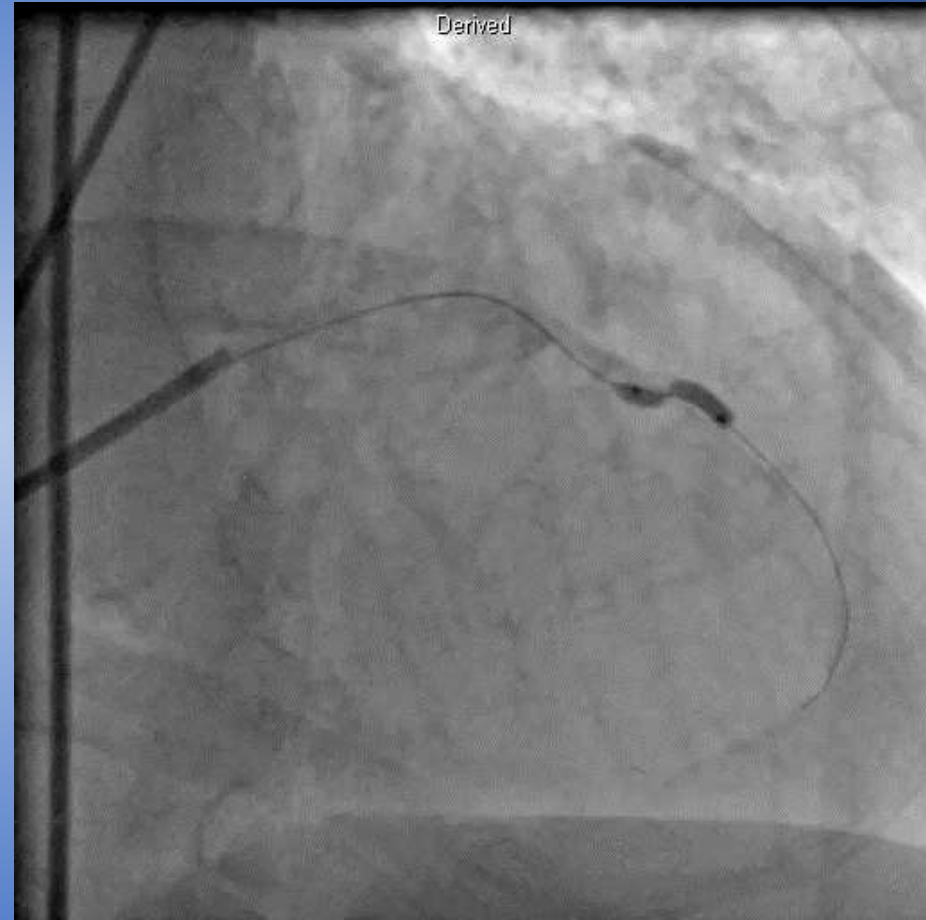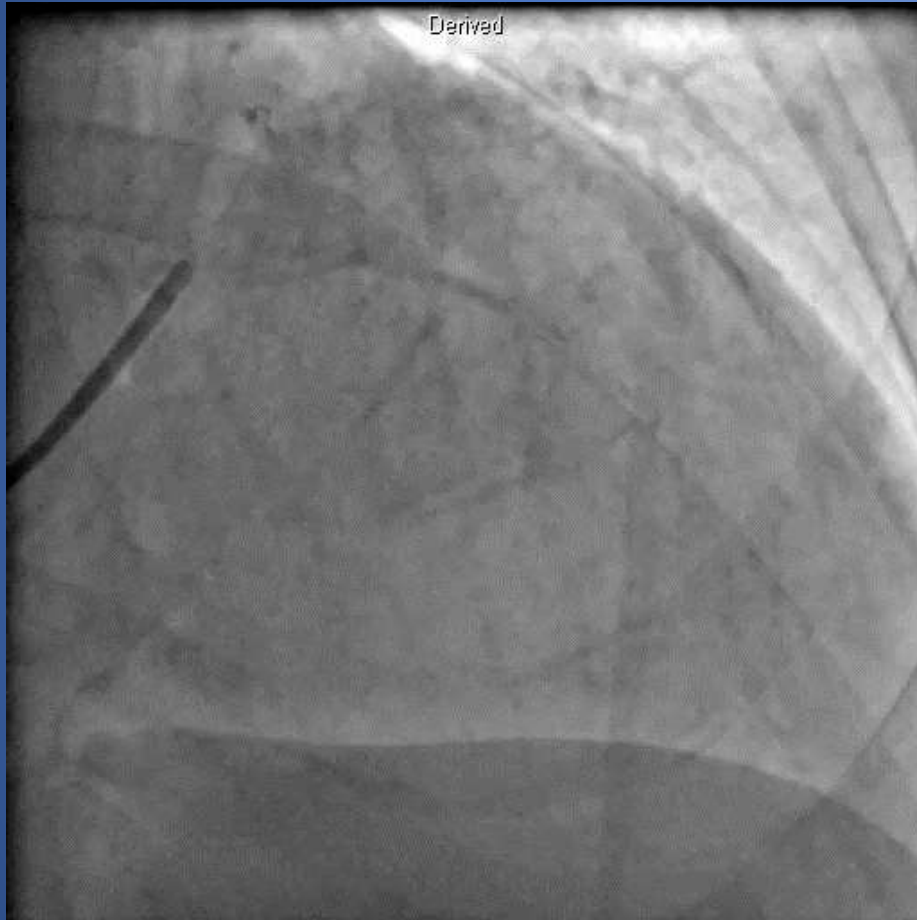- 30 micron diamond coating
- Bi-directional sanding, eccentric mounted crown
- Healthy elastic tissue flexes away minimizing damage to the vessel

Centrifugal Force:

- 360° crown contact designed to create a smooth, concentric lumen
- Allows constant blood flow and particulate flushing during orbit
- Increasing speed increases orbital diameter
- Ability to treat multiple vessel diameters with one crown (1.25 mm)
- Treat large vessels through small sheaths

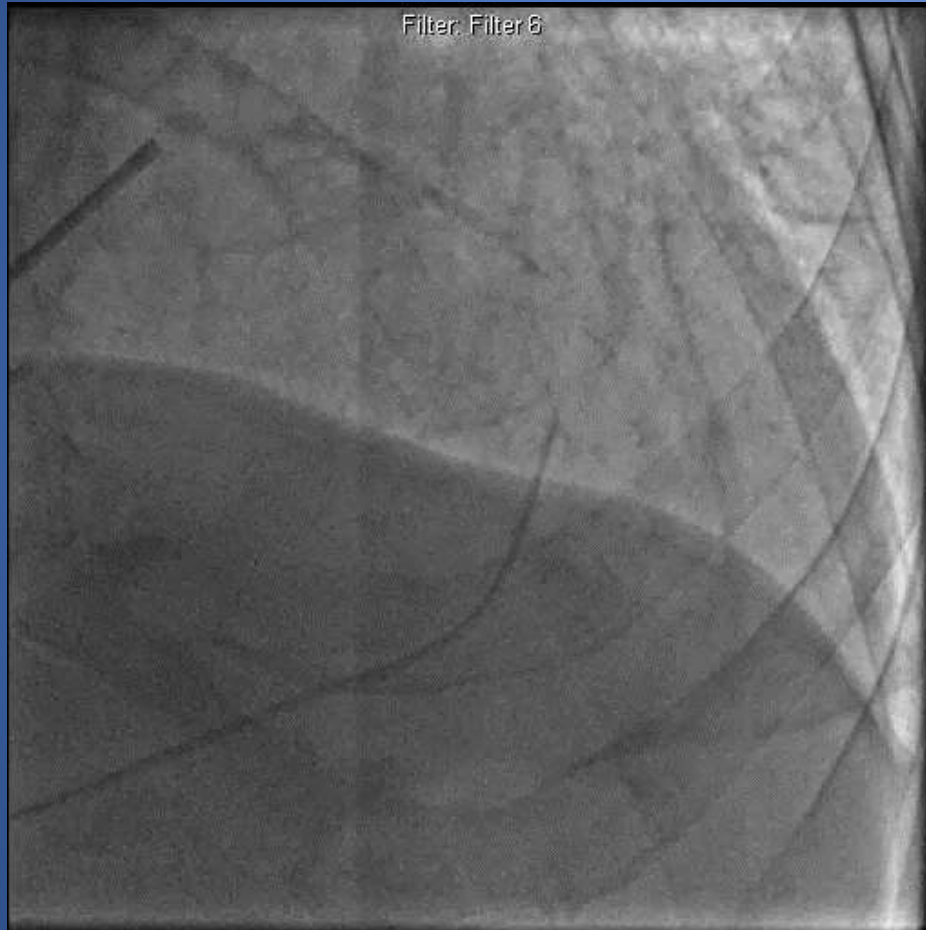

76 y.o. male with unstable angina
PMH: smoking, HTN

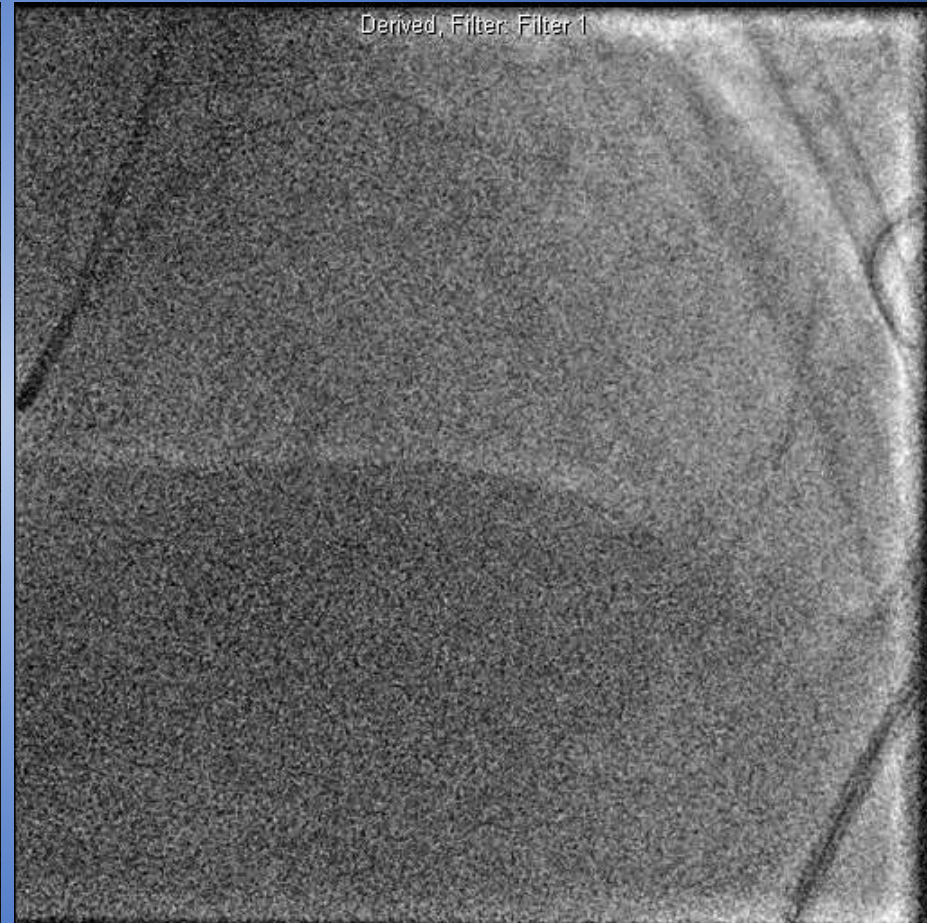


Severe proximal LAD stenosis

Unable to dilate calcified lesion



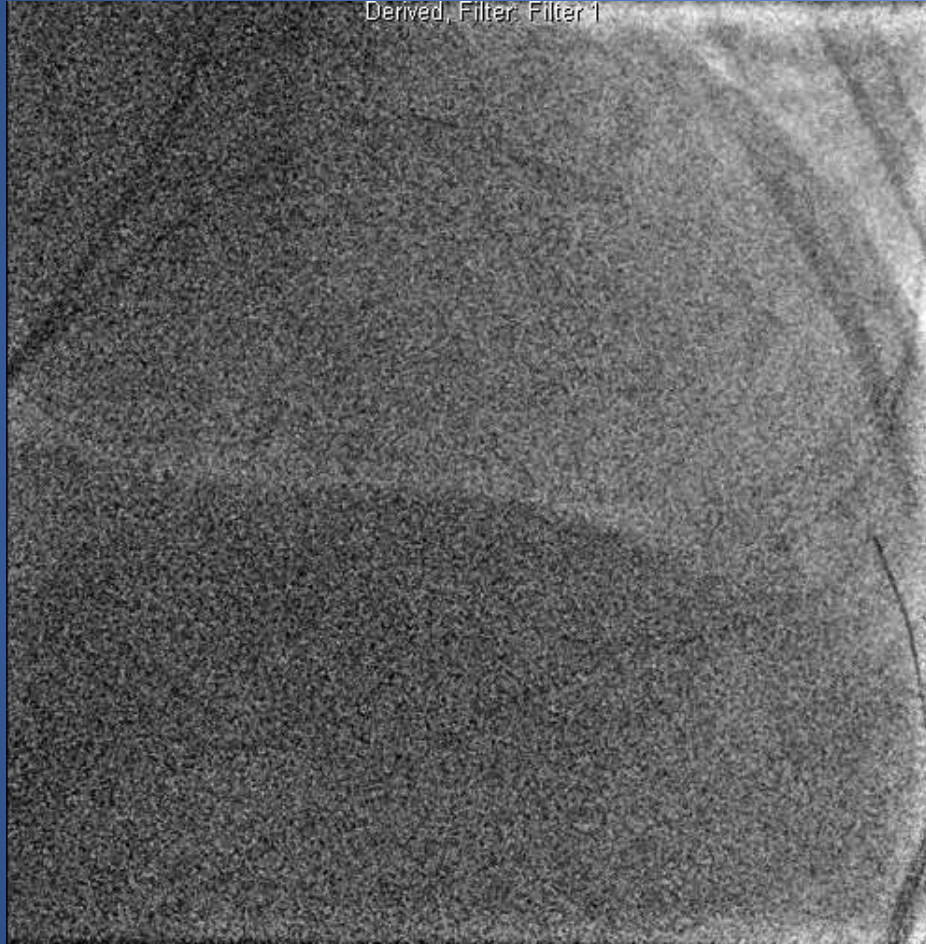
Angiography at 1 week shows pseudo-aneurysm of LAD



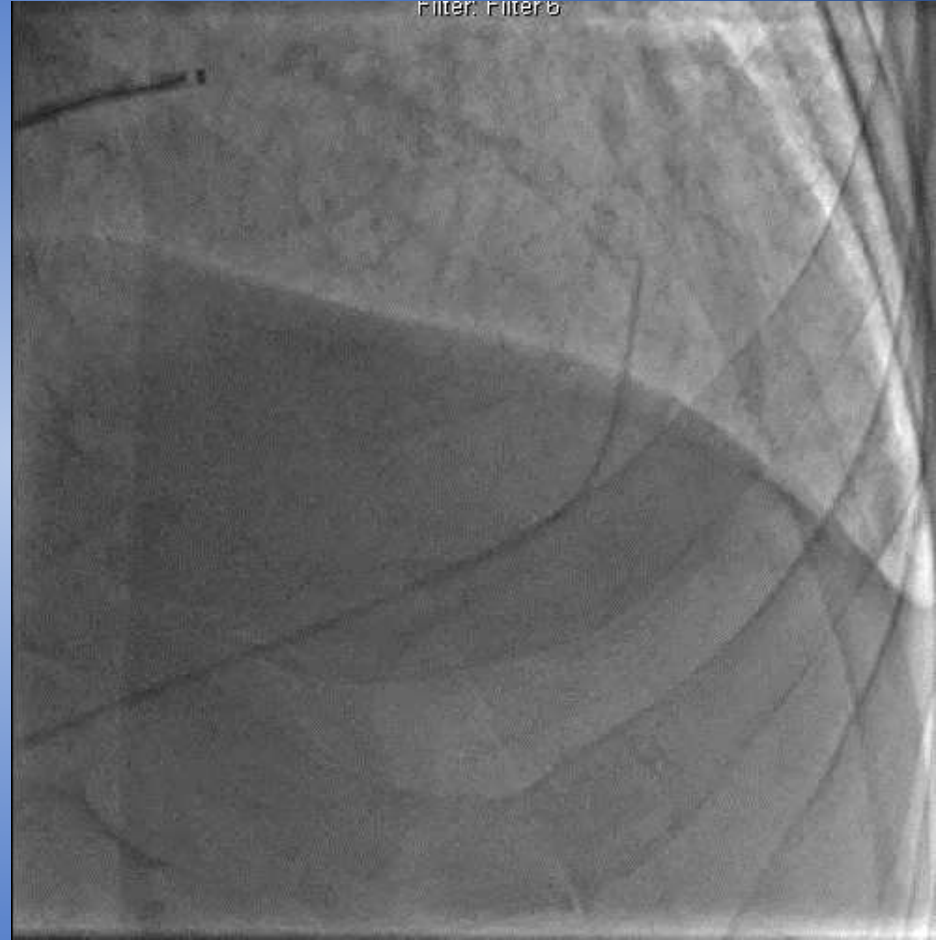Difficulty wiring

Look, Listen, and Feel

Derived, Filter: Filter 1



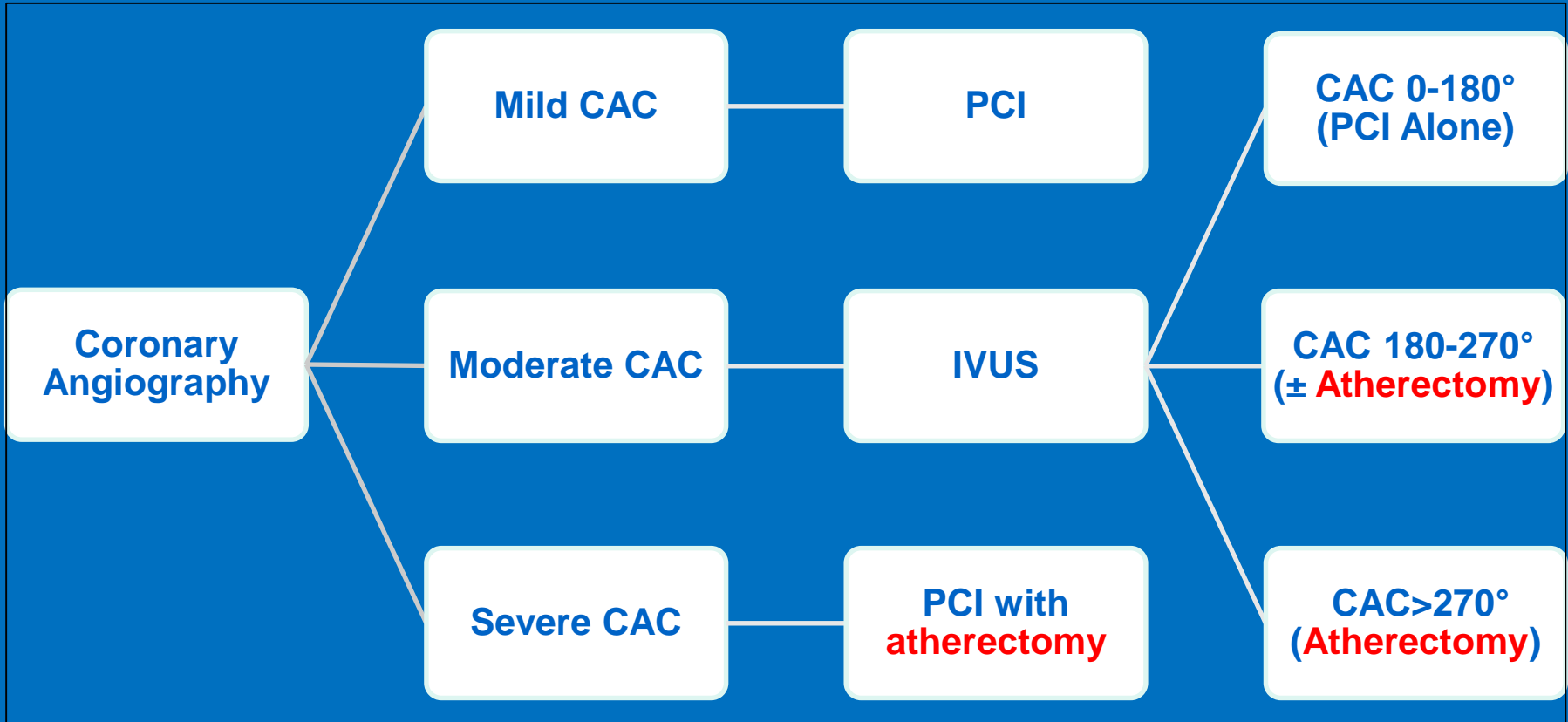
Filter: Filter b



- Advance 1 mm/second. Max 25 seconds
- Continue low-speed until change in cadence
- Slow, pecking. Never push

Final angiography

Treatment Algorithm



ORBIT II: Study Design

To evaluate safety and efficacy of the Diamondback Coronary OAS Classic Crown to prepare *de novo*, **severely calcified coronary lesions** for enabling stent placement

- Prospective, multi-center trial in the United States
- Single arm - As there were no FDA-approved percutaneous treatments specifically for patients with severely calcified coronary lesions.
- **443 subjects enrolled at 49 U.S. Sites**

30 day
follow-up*
(N=437/440)

1-year
follow-up†
(N=434/440)

2-year
follow-up‡
(N=424/440)

3-year
follow-up#
(N=411/440)

- **Primary Safety Endpoint: MACE** (MI= CK-MB>3x ULN, TVR, Cardiac Death)
- **Primary Efficacy Endpoint: Procedural Success**
 - Success in facilitating stent delivery with a final residual stenosis of <50% (as determined by Angiographic Core Lab) and free from in-hospital MACE

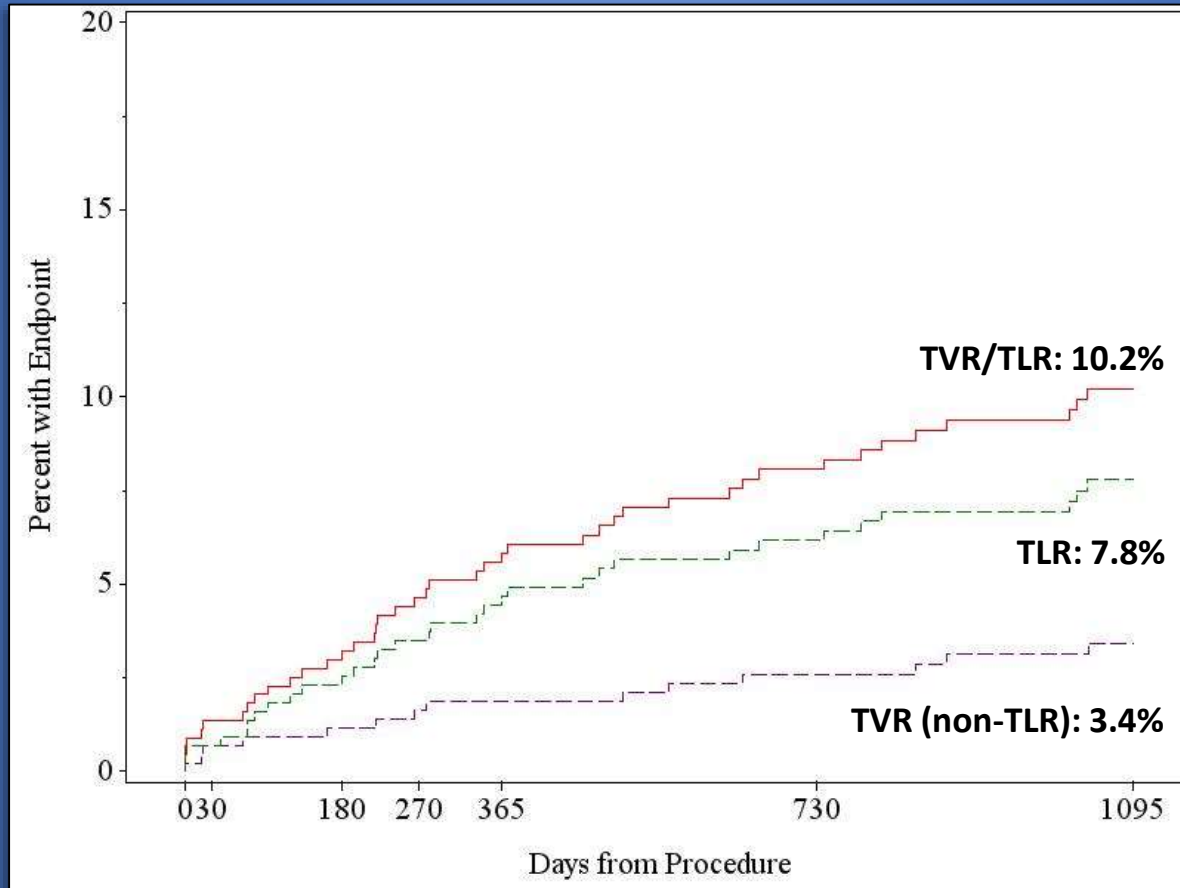


*438 subjects per Kaplan Meier were at risk/events for MACE
†432 subjects per Kaplan Meier were at risk/events for MACE
‡411 subjects per Kaplan Meier were at risk/events for MACE
#311 subjects per Kaplan Meier were at risk/events for MACE
Lee MS, et al. Cardiovasc Revasc Med. 2017;18:261-264.



ORBIT II

3-Year TVR/TLR



<i>Number at risk (TVR/TLR)</i>	443	430	413	403	392	356	228
<i>Number at risk (TLR)</i>	443	432	415	407	396	363	234
<i>Number at risk (TVR)</i>	443	433	421	416	407	377	242

Real-World Multicenter Experience on Patients with Severe Coronary Artery Calcification Undergoing Orbital Atherectomy

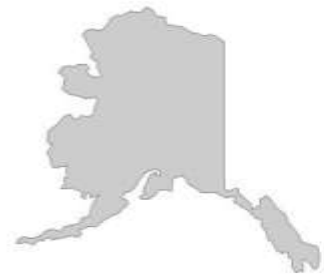Participating Sites

- Retrospective study
- 458 consecutive patients with severe CAC who underwent orbital atherectomy followed by stenting
- October 2013 to December 2015

Ucla



St. Francis Hospital
The Heart Center
Catholic Health Services
At the heart of health



Angiographic Complications

© 2016, Wiley Periodicals, Inc.
DOI: 10.1111/joic.12310

ORIGINAL INVESTIGATION

Real-World Multicenter Registry of Patients with Severe Coronary Artery Calcification Undergoing Orbital Atherectomy

MICHAEL S. LEE, M.D.,¹ EVAN SHLOFMITZ, D.O.,² BARRY KAPLAN, M.D.,²
DRAGOS ALEXANDRU, M.D.,² PERWAIZ MERAJ, M.D.,² and RICHARD SHLOFMITZ, M.D.³

From the ¹Division of Interventional Cardiology, UCLA Medical Center, Los Angeles, California; ²Division of Cardiology, Northwell Health, Manhasset, New York; and ³Division of Cardiology, St. Francis Hospital, Roslyn, New York

Objectives: We evaluated the safety and efficacy of orbital atherectomy in real-world patients with severe coronary artery calcification (CAC).

Background: The presence of severe CAC increases the complexity of percutaneous coronary intervention as it may impede stent delivery and optimal stent expansion. Atherectomy may be an indispensable tool for uncrossable or undilatable lesions by modifying severe CAC. Although the ORBIT I and II trials report that orbital atherectomy was safe and effective for the treatment of severe CAC, patients with kidney disease, recent myocardial infarction, long diffuse disease, severe left ventricular dysfunction, and unprotected left main disease were excluded.

Methods: This retrospective study included 458 consecutive patients with severe CAC who underwent orbital atherectomy followed by stenting from October 2013 to December 2015 at 3 centers.

Results: The primary endpoint of major adverse cardiac and cerebrovascular events at 30 days was 1.7%. Low rates of 30-day all-cause mortality (1.3%), myocardial infarction (1.1%), target vessel revascularization (0%), stroke (0.2%), and stent thrombosis (0.9%) were observed. Angiographic complications were low: perforation was 0.7%, dissection 0.9%, and no-reflow 0.7%. Emergency coronary artery bypass graft surgery was performed in 0.2% of patients.

Conclusion: In the largest real-world study of patients who underwent orbital atherectomy, including high-risk patients who were not surgical candidates as well as those with very complex coronary anatomy, acute and short-term adverse clinical event rates were low. A randomized clinical trial is needed to identify the ideal treatment strategy for patients with severe CAC. (J Intervent Cardiol 2016;9999:1–6)

	n=458
Perforation	3 (0.7%)
Dissection	4 (0.9%)
No reflow	3 (0.7%)



Lee MS, et al. J Interv Cardiol 2016.



30-day Clinical Event Rates

	n=458
MACE	8 (1.7%)
Death	6 (1.3%)
Myocardial infarction	4 (1.1%)
Target vessel revascularization	0 (0.0%)
Stroke	1 (0.2%)
Stent thrombosis	4 (0.9%)
Emergent CABG	1 (0.2%)

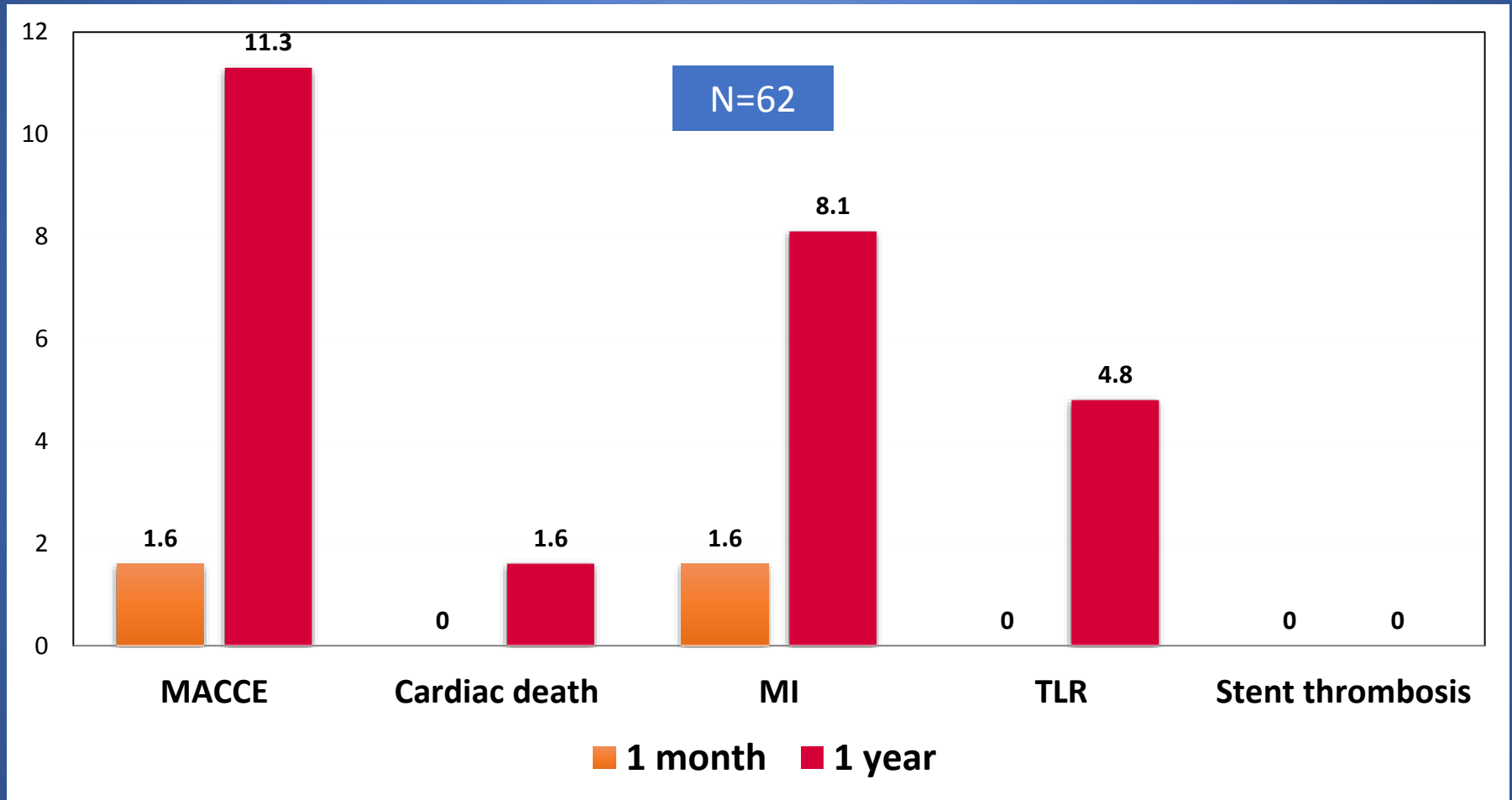
Values are n (%)



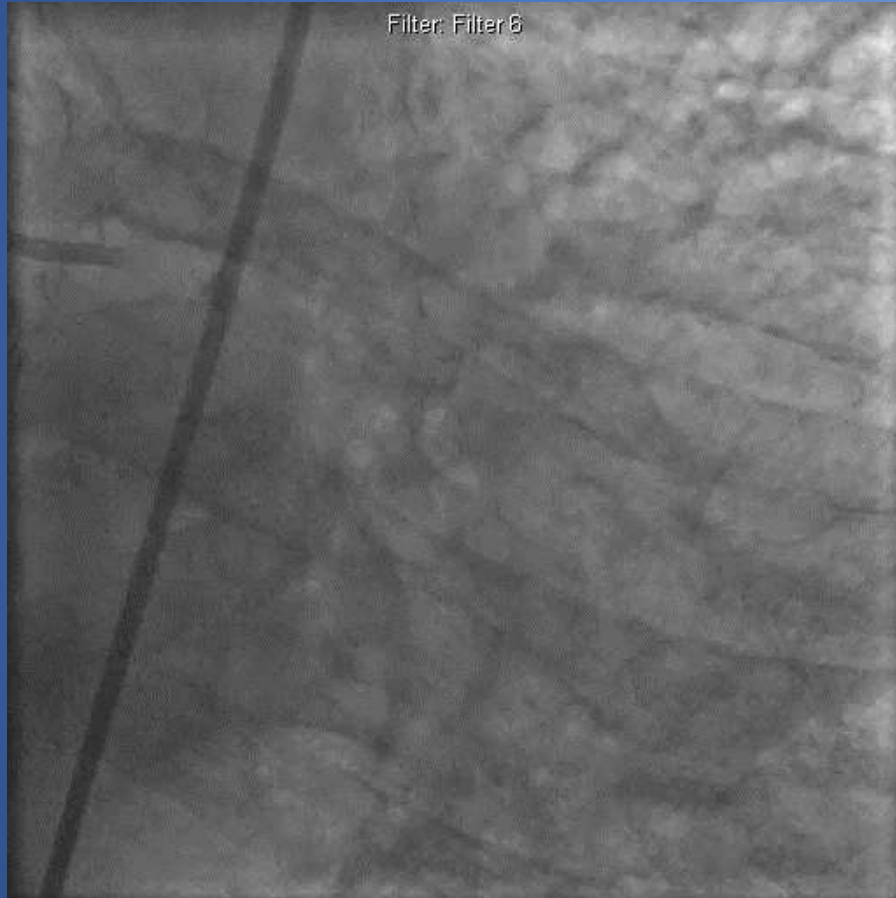
Lee MS, et al. J Interv Cardiol 2016.



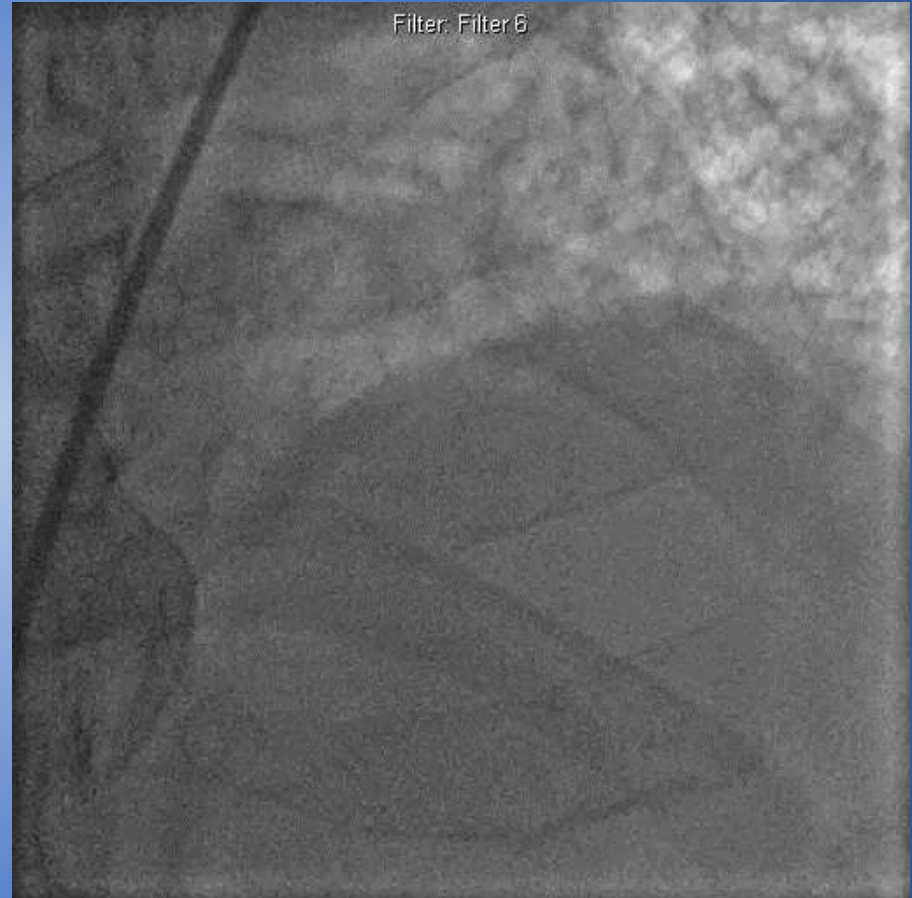
Orbital Atherectomy for Unprotected Left Main Disease



Calcified Left Main and LAD





68 y.o. male pre-lung transplant



Calcified LM and LAD

Orbital Atherectomy Left Main Artery

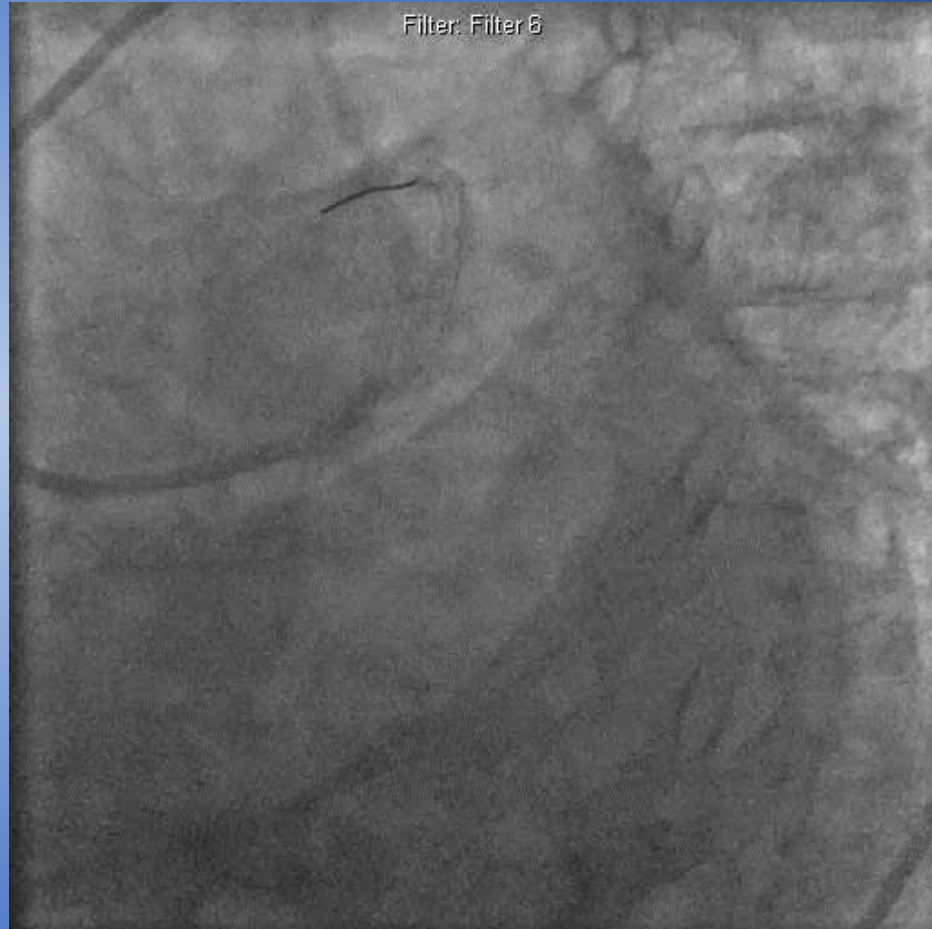
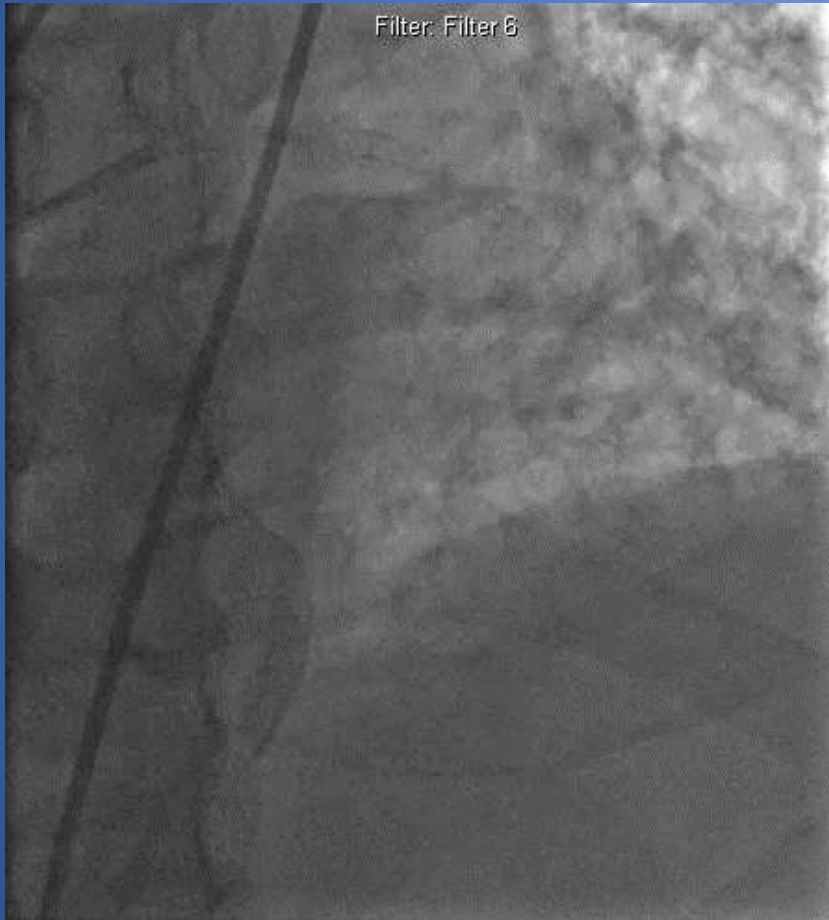Derived, Filter: Filter 1



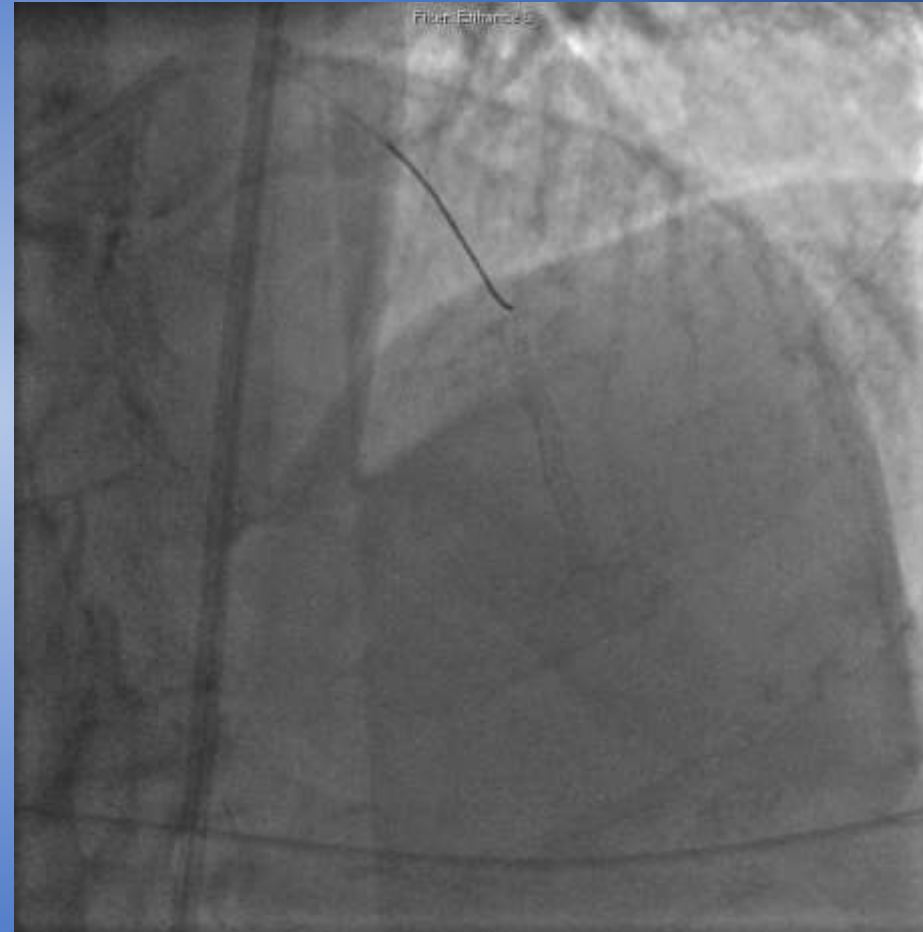
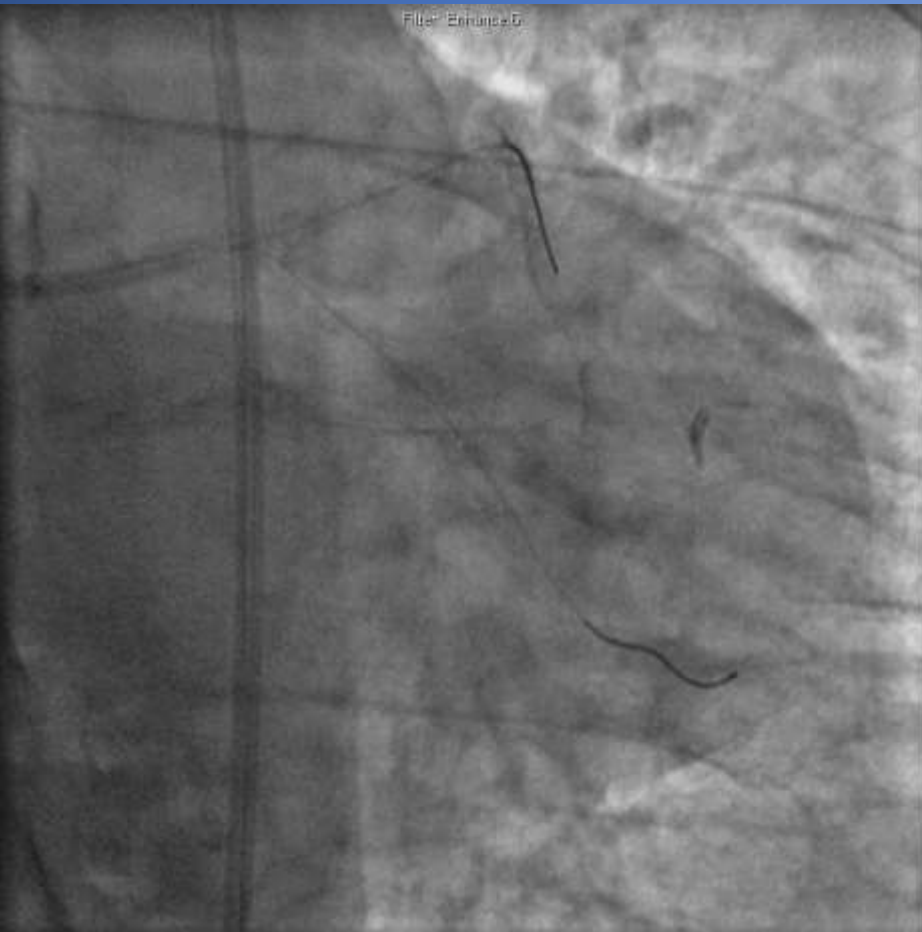
Treats 360° of the vessel. The diamond coated crown sands away calcium and allows healthy elastic tissue to flex away minimizing injury to the vessel.



Final Angiography



Rotational Atherectomy of Large Left Main Bifurcation



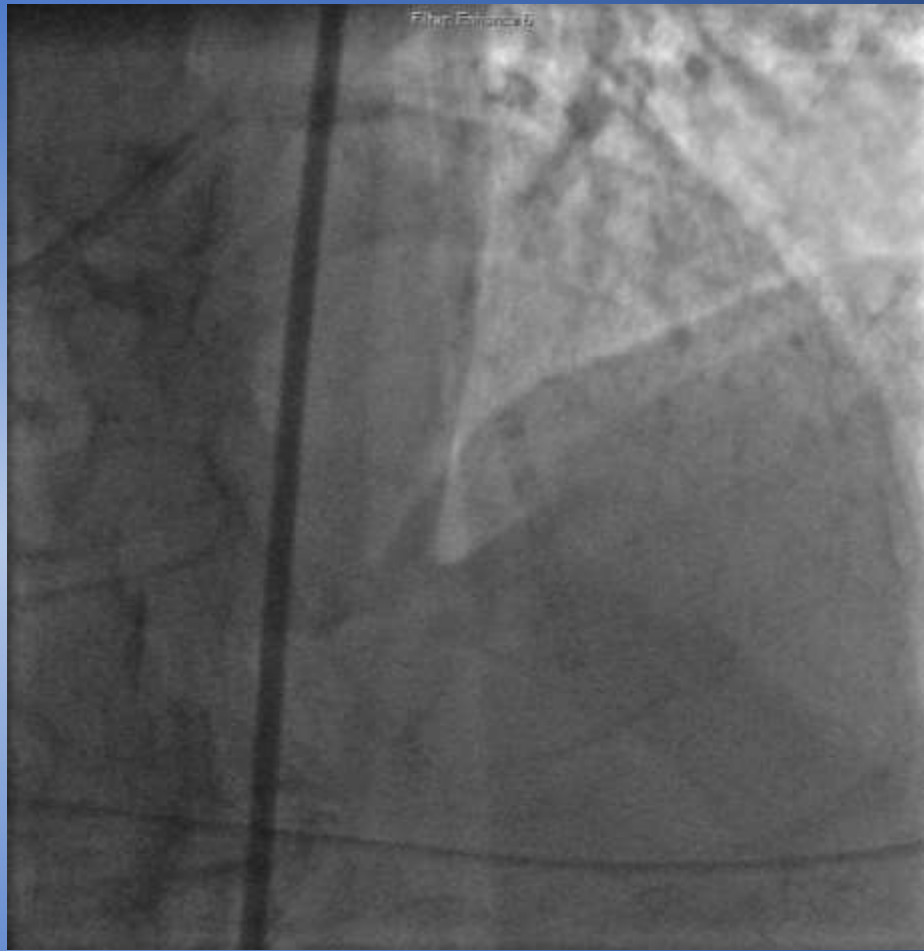
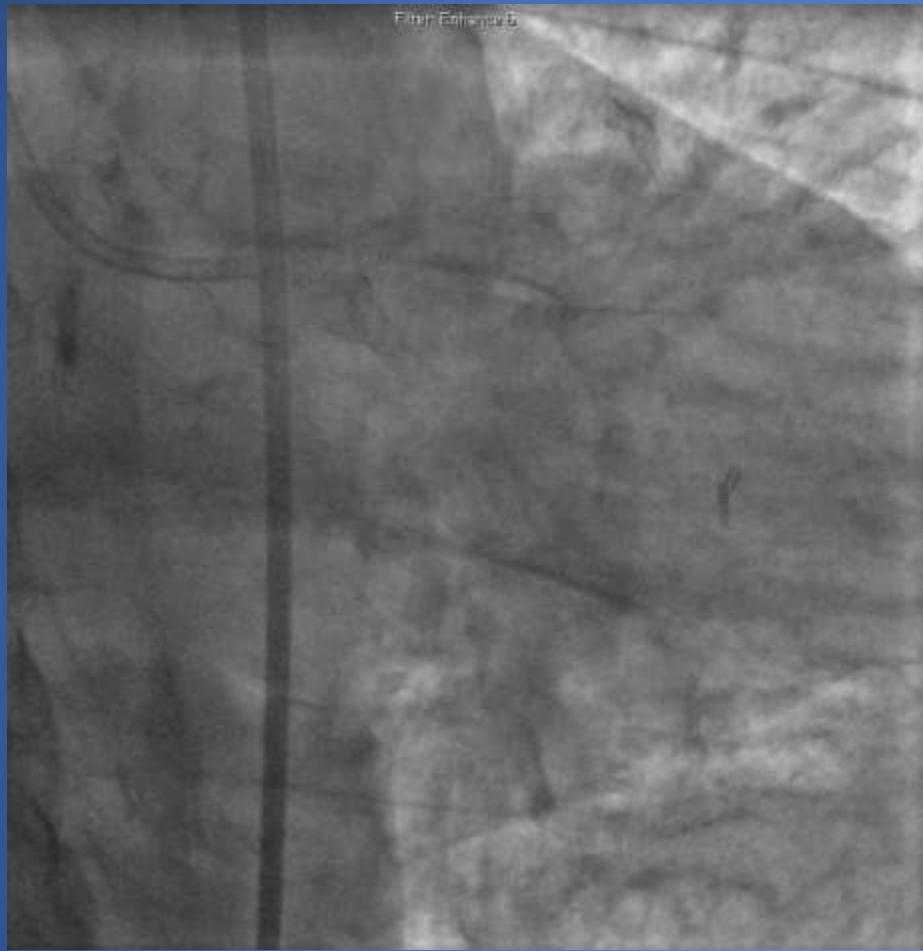
Filter Entrance 9

Filter Entrance 6

Mini-Crush technique

Kissing balloon technique





Conclusion

- Coronary artery calcification may prevent stent delivery and optimal stent expansion
- CAC is associated with increased risk of complications, including death, MI, TVR, and stent thrombosis
- Coronary atherectomy is a safe and effective treatment strategy for patients with severe CAC
- Low angiographic complications
- Acceptable rates of TVR





John Wooden

“Failing to prepare is preparing to fail”

